

SELF-MUTILATION IN UROLOGIC PATIENTS - CASE REPORT

Radoš. Zikić (1), Zvonimir Adamović (2), Zoran Jelenković (3)

(1) POLIKLINIKA PAUNKOVIĆ, TIMOČKE BUNE 4, ZAJEČAR; (2) ZDRAVSTVENI CENTAR ZAJEČAR, RASADNIČKA BB; (3) RFZO – FILIJALA ZAJEČAR

Summary: Self-mutilation is intentionally injuring oneself. Generally, the most common self-inflicted wounds are burns and cuts which can be closed and open. In extreme cases it could be a suicidal attempt. In urology, genitals are usually the object of mutilation. Because of their anatomical features and topographic location, they are most commonly exposed to these procedures. There may be cuts on the penis, perineum, scrotum; scrotum avulsion, orchiectomy, castration to penile amputation. These are mental patients suffering from paranoid schizophrenia. As part of their delusions, they have bodily-cinesthetic hallucinations that manifest discomfort in the genital area. There is a delusional idea that the only solution to eliminate the hallucinations present is to self-mutilate. Because these organs are very blood-borne, they are always shocked after the ritual because of bleeding and pain. We present a 46-year-old patient with severe genital injury, scrotum avulsion, and subtotal penile amputation. Since more than 2 hours had passed since self-mutilation, the suture of the penis could not be done, so after resuscitation, a suture of the scrotum, tunica albuginea and an external urethral opening were done. After leaving the recovery room, he was transferred to a psychiatric ward and later to a higher health care facility.

Key Words: paranoid schizophrenia, self-mutilation, penil amputation.

INTRODUCTION

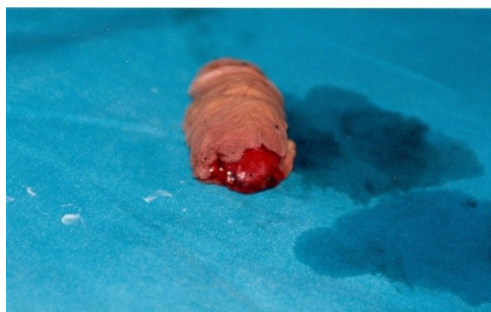Self-mutilation represents intentionally injuring oneself. Most frequently these are cuts or burns. It is often a way for a person to deal with emotional problems.

Very rarely it is a suicidal attempt. Due to their anatomic features and topographic position, male genitals are exposed to injuries even if they are covered by clothes and protected. Injuries can be injuries at work, while doing sports, in traffic accidents, sexual injuries

caused by masturbation and in sexual ecstasy unintentionally or in acute affectivity intentionally. The wounds can be closed and open.

Amputation is one of the most severe injury of male genitalia, an extremely rare injury and it includes a complete or partial interruption of the continuity of the body of the penis [1]. Complete amputation is characterized by cutting the corpora cavernosa and urethra and partial by cutting only one part of it. (Figure 1).

Figure 1. Complete amputation



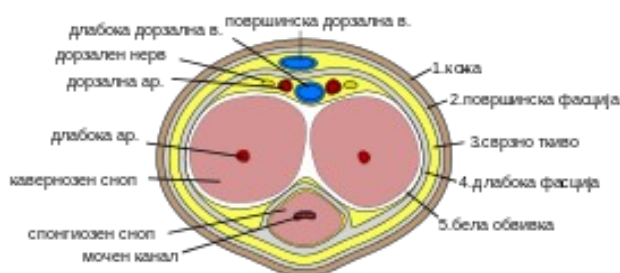
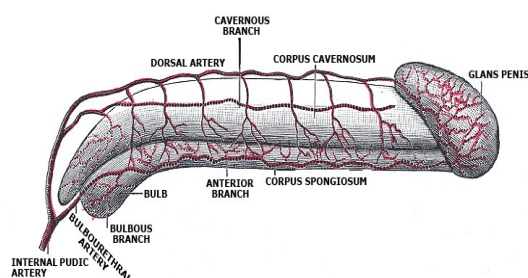
The penis is an organ which is anatomically divided into three parts: the base of the penis, the shaft of the penis and the glans penis. The base is located below the pubic bone and it

provides the firmness of the penis in erection. The shaft consists of two cavernous parts and one spongy part. The urethra runs through the spongy part to the external urethral orifice -

meatus, located at the tip of the glans penis. They are also called erectile bodies because they enable erection of the penis. The glans is a distal expansion of the spongy part covered with mobile skin – Prepuce.

The penis is innervated from the right and left dorsal nerves and from the branches of the pudendal nerve. It is vascularized by the internal pudendal artery of the femoral artery branch (SHEMA 1).

SHEMA 1. ANATOMICAL DETAILS: VASCULARISATION OF PENIS AND TRANSVERSAL SECTION OF PENIS.



Open injuries of the penis are most often inflicted with firearms or sidearms. Complete or total amputation is characterized by cutting the cavernous parts and the urethra.

History records a special way of amputation of the penis (as a part of castration) in eunuchs, which dates from the 21st century BC. Over the centuries eunuchs performed various duties in various cultures as temple guardians, opera singers, soldiers, clerks [2,3]. Cases of sexual aggression were described as the causes for penis amputation. For 70 years in Thailand women amputated the penises of their husbands caught in adultery [4]. The diagnosis is obvious on the basis of physical examination. Through a detailed anamnesis one can reach the reason for the injury and the mental state of the patient [5]. Considering that these organs have very high blood flow, the open wounds are accompanied by heavy bleeding, and the person is shocked by the pain and hemorrhage. In such cases, after resuscitation, surgery takes place. Treating the wounds with large tissue defect requires application of the methods of plastic and reconstructive surgery, which uses skin flaps taken from the skin of the scrotum, pubic region, abdomen [6]. Sex-related injuries of external genitalia should be treated multidisciplinary and not only surgically with antitetanus protection always applied.

CASE STUDY

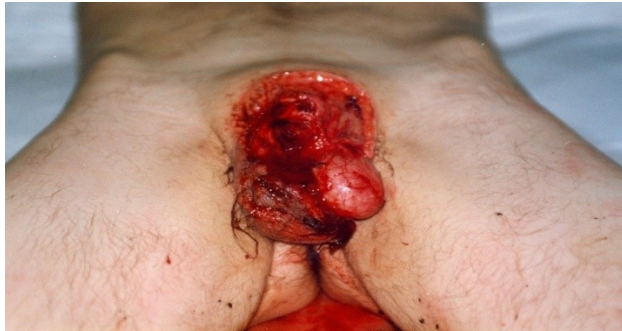46 years old man, from around Zaječar, came to the urology department in the morning,

accompanied by his father. Pale, in poor general condition. At the reception the father takes a nylon bag from his pocket which contained a cut off penis. Examination under cotton-wool soaked with blood reveals an open wound with the left testicle outside the scrotum and subtotal amputation of the penis. Urgent laboratory showed haemoglobin to be 72 g/l. In heteroanamnesis, Patient is divorced, has a 17-year-old son who lives with his mother while he himself lives with his parents. He had been treated from schizophrenia for a long time and kept calling himself Zorana. The day before he came to the department he put a mirror in front of himself at the height of his genitalia and with a slashing knife began to rearrange his gender identity (Figures 2 and 3). Accidentally his mother came into his room finding him in the pool of blood.

After urgent resuscitation there followed a surgical care of the injury. Scrotal injuries were sutured first, followed by restitution of the cavernous part and suturing of tunicae albuginae. Then drainage. The external opening of the urethra was formed. A catheter was inserted.

Upon leaving the recovery room, the patient was transferred to a psychiatric ward, from where he was further transferred to a higher health institution – Specialized hospital for psychiatric diseases “Gornja Toponica”.

Figure 2. Amputation of the penis and open wound of the scrotum.



DISCUSSION

All sexual actions including those sexually deviant which can result in mutilation of genitalia take shape in the brain [1]. The wounds can be closed and open. Closed wounds on the penis take place accidentally during sex when the penis is in erection (Penile fracture), because of the rupture of tunicae albuginae blood from the cavernous part forms a hematoma subcutaneously. Open wounds can come from the other person or very rarely in self-mutilation from cuts on the scrotum (with cutting off of the sheaths with testicles outside the scrotal sac), cuts on the penis, amputation of the penis. Through careful anamnesis one can get to know the causes of the injury. Depending on the objective findings therapy is introduced. Injuries on the scrotum are repaired – after refreshing the edges and hemostasis, if the testicles are outside the scrotum, they return to the scrotal sac, the sheaths are sutured, there follows subcutaneous drainage and suture of the skin. If it's been less than 2 hours since the amputation, it is possible to perform a suture with microsurgery in higher professional institutions [6,7]. In other cases, after resuscitation, proper hemostasis and urethral restitution for normal urinations should be performed.

Traumatic penile amputation is a rare urological and surgical emergency. A systematic review of 80 cases from 1996 to 2007 reported only 37.5% of cases that underwent successful re-implantation [8]. The main etiology of penis amputation is self-mutilation, accidents, circumcision, seizures and animal attacks. As early as the 1970s, an epidemic of penis amputations was recorded from Thailand, where women amputated their husbands' genitals due to infidelity. This series of cases of 18 patients is still the largest to date [4].

Figure 3. Amputated part of the penis. 161



schizophrenia (Schizophrenia paranoides). As part of his insanity, he has body-synesthetic hallucinations (synesthesia, the ability of one uns stimulated sense to feel the stimulus of another sense), which is manifested by discomfort in the area of the sexual organ. There is a crazy idea that the only solution to remove the present hallucinations is to cut the genitals, which he does, giving a crazy explanation "to become a woman". Because of that, after the surgical care, he was sent to a mental hospital.

CONCLUSION

We have presented an extremely rare case of self-harm. Restitution of the severed penis was not attempted, as more than 2 hours had passed from the moment of penis cut-off to the arrival at the urology department. The bleeding was not more copious because the penis was not in erection.

After resuscitation, the scrotum, tunica albuginae and the shape of the external opening of the urethra were performed. After leaving the shock room, he was transferred to the psychiatric department.

REFERENCES:

1. Sava P. Urologija, Medicinska knjiga, 1984; 731-738.
2. Jordan GH, Gilbert DA. Management of amputation injuries of the male genitalia. Urol. Clin. North. Am. 16, 1989; 359-367.
3. Radić P. Carigrad, Priče sa Bosfora, Evoluta. Beograd, 2007; 62-72.
4. Kasian Bhanaganada MD, Tu Chayavatana, Chumporn Pongnumkul, Anunt Tonmukayakul, Piyasakol Sakolsatayadorn, Krit Komaratat et al. Surgical management of an epidemic of penile amputations in Siam. The American Journal of Surgery 1983;146(3):376-382. Available from: [https://doi.org/10.1016/0002-9610\(83\)90420-8](https://doi.org/10.1016/0002-9610(83)90420-8).
5. Kochakam W. Traumatic amputation of the penis. Brazilian Journal of Urology, 2000; 26: 385.
6. Tushar Patial, Girish Sharma, and Pamposh Raina Traumatic penile amputation: a case report. BMC Urol. 2017; 17: 93. Published online 2017 Oct 10. doi:10.1186/s12894-017-0285-4.
7. Jezior JR, Brady JD, Schlossberg SM. Management of penile amputation injuries. World J Surg. 2001;25(12):1602-1609. doi: 10.1007/s00268-001-0157-6.
8. Babaei AR, Safarinejad MR. Penile reimplantation, science or myth? A systematic review. Urol J. 2009;4(2):62-65.